Published online: 2021-12-23

Percutaneous Cryoanalgesia: A New Strategy for Pain Management in Pectus Excavatum Surgery

María Velayos[1] Mercedes Alonso[2] Carlos Delgado-Miguel[1] Karla Estefanía-Fernández[1] Antonio J Muñoz-Serrano[1] Manuel V López Santamaría[1] Francisco Reinoso-Barbero[2] Carlos A De La Torre[1]

[1] Pediatric Surgery Department, La Paz University Hospital, Madrid, Spain
[2] Children's Anesthesia and Resuscitation Department, La Paz University Hospital, Madrid, Spain

Address for correspondence María Velayos, MD, Pediatric Surgery Department, La Paz University Hospital, Paseo de la Castellana 261, 28046, Madrid, Spain (e-mail: mariavelayos@icloud.com).

Eur J Pediatr Surg

Abstract

Introduction In recent years, pain protocols for pectus excavatum (PE) have incorporated cryoanalgesia through thoracoscopic approach. Since 2019, ultrasound-guided percutaneous cryoanalgesia (PCr) has been applied at our institution, either on the same day as the Nuss procedure or 48 hours before surgery. We carried out a preliminary retrospective review of patients with PE in whom PCr prior to surgery was performed at our institution between 2019 and 2021.

Materials and Methods Two groups were evaluated: PCr on the same day (PCrSD) and PCr 48 hours before surgery (PCr48). Despite PCr, patients were treated with "patient-controlled analgesia" (PCA) with opioids for at least 24 hours, switching to conventional intravenous analgesia and oral analgesia in the following days. Demographic, clinical-radiological variables, PCA opioid use, pain grade according to the visual analog scale (VAS), and length of stay (LOS) were compared between the groups. A total of 20 patients were included (12 with PCrSD and 8 with PCr48), without significant differences in demographics or clinical-radiological variables. The overall median time of PCr was 65 minutes (55–127), with no differences between the groups.

Results PCr48 group presented with significantly lower median number of hours of continuous PCA (24 vs. 32 hours; $p = 0.031$), lower median number of rescue boluses (11 vs. 18; $p = 0.042$), lower median VAS in the early postoperative hours (2 vs. 5.5; $p = 0.043$), and lower median LOS (3.5 vs. 5 days).

Conclusion PCr performed 48 hours prior to surgery is more effective in terms of PCA requirements, VAS, and LOS when compared with cryoanalgesia on the same day.

Keywords
- pectus excavatum
- cryoanalgesia
- percutaneous
- ultrasonography
- pain

Introduction

Pectus excavatum (PE) is the most common chest wall deformity.[1] Over several decades, the Nuss procedure has become the technique of choice.[2–5] However, the success of this procedure coexists with severe postoperative pain even after discharge home, long hospital stays, and a high consumption of opioids-like analgesics, which pose a challenge to the patient, family, and physician.[6–10]

Adequate postoperative pain control is the main determinant of hospital stay after the Nuss surgery.[11–13] Poor pain control not only increases hospital stay, but also can raise opioid consumption, limit mobility, or favor readmissions. Different strategies have been developed to try to mitigate

received
July 17, 2021
accepted after revision
October 21, 2021

© 2021. Thieme. All rights reserved.
Georg Thieme Verlag KG,
Rüdigerstraße 14,
70469 Stuttgart, Germany

DOI https://doi.org/10.1055/s-0041-1740555.
ISSN 0939-7248.

Downloaded by: HOSPITAL LA PAZ. Copyrighted material.

postoperative pain and its consequences, such as the use of multimodal analgesic therapies, thoracic epidural catheters, elastomeric pain pumps, or intravenous patient-controlled analgesia (PCA), with limited results in the reduction of long-term postoperative pain.[2,12,14–16] In recent years, thoracoscopic cryoanalgesia has gained great relevance and has become the standard technique in many centers. Its origin dates back to the time of Hippocrates (470–377 BC), who was the first to observe how ice and cold numb and relieve pain, and since then it has been developed and improved, offering long-lasting pain control, shorter hospital stay, and less opiate consumption.[2,6,17] However, its application means longer surgical time and higher surgical costs related to the performance of bilateral thoracoscopy and hence it is not free of complications (wound infection, pneumothorax, pleural effusion, etc.).

At our institution, all efforts in recent years have been directed toward improving the postoperative course of patients undergoing PE surgical correction by performing ultrasound-guided percutaneous cryoanalgesia (PCr), which is a less invasive technique than thoracoscopy and is easy to apply, reproducible, and safe. The aim of the study was to compare the efficacy of PCr performed 48 hours before surgery versus the one performed on the same day of surgery.

Material and Methods

Study Design

Data from a prospectively collected database were reviewed and analyzed retrospectively in children who underwent PE surgical correction by the Nuss technique at our institution from January 2019 to January 2021. They were classified into two groups according to the time of PCr application: the same day of surgery (PCrSD) and 48 hours before surgery (PCr48). The mode of attribution of patients to one group or the other was performed in the consultation prior to surgery, after an interview on the possible risks and benefits of the two strategies, between the surgeon, the anesthesiologist, the patient, and his/her family. Demographic variables, clinical-radiological features, operation time, analgesic use (hours of continuous PCA and rescue boluses), pain grade (VAS), hospital stay, intraoperative and postoperative complications, and short-term follow-up were evaluated. Patients older than 18 years or younger than 13 years, chest wall different than PE (e.g., pectus carinatum, pectus arcuatum), previous thoracic surgery, chronic use of analgesics, or any anesthetic contraindication were excluded. Informed consent signed by the parents or legal guardians was obtained prior to surgery in the outpatient clinic.

Cryoanalgesia Protocol and Nuss Procedure

Patients in the PCr48 group were admitted to the hospital on the same day and PCr was applied. Fasting was checked; we also checked whether the patients were suitable in the preanesthetic evaluation, as well as whether the informed consent form was correctly completed by the parents or legal guardians. In the case of the application of PCrSD, the patients were admitted the previous day for cross-matching tests and fasting guidelines. Similarly, we checked for preanesthesia aptitude and whether the informed consent form was correctly completed.

The protocol used and the anesthesiologist in charge of performing the procedure were the same in all patients. Prior to the start of the procedure, the calibration of the machines and the condition of all the material to be used were checked. After entering the operating room, inhalation anesthetic induction was performed with sevoflurane, peripheral line cannulation for maintenance anesthesia with propofol and fentanyl, administration of magnesium metamizole and ondansetron. All patients remained in spontaneous breathing with laryngeal mask. The position performed was right lateral decubitus inclined at 45 degrees. Under sterile technique and ultrasound control, the desired intercostal space was located and an 18-G angiocatheter was introduced until the tip was located inside the internal intercostal muscle; once there, the angiocatheter was slightly withdrawn and the needle was removed. Subsequently, the cryoanalgesia needle (needle model A-08/20/N/RF with rounded tip, 9-cm length, 7-mm freezing tip, and 21-mm thickness [Metrum Cryoflex; Cryo-S Electric II Painless equipment, Warsaw, Poland]) was introduced up to the intercostal nerve and a simple freezing cycle was applied for 2 minutes with carbon dioxide at −70°C, followed by 30 to 60 seconds of thawing (►Fig. 1 and ►Fig. 2). Finally, the needle and angiocatheter were removed. This same procedure was repeated from T3 to T7 in both hemithoraces. Once the procedure was completed, the absence of complications was checked and the patient was awakened in the case of PCr48 and discharged home within hours or, in the case of PCrSD, the Nuss procedure was continued.

The minimally invasive repair was performed by the same surgeon in all cases. The same general repair protocol was followed for all patients: sternal elevation with crane technique, two small incisions on each side of the chest wall, a subcutaneous tunnel for rod insertion, and a superior lateral incision in the posterior axillary line for camera insertion. Under thoracoscopic vision, a retrosternal space was created below the point of greatest sternal collapse, and an introducer was advanced through the mid-zone and externalized

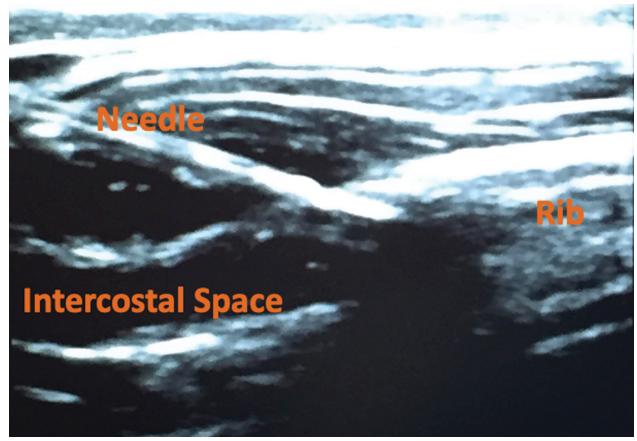

Fig. 1 Ultrasound image of percutaneous cryoanalgesia. The cryoanalgesia needle enters the intercostal space just below the rib.

 © 2021. Thieme. All rights reserved.

Downloaded by: HOSPITAL LA PAZ. Copyrighted material.

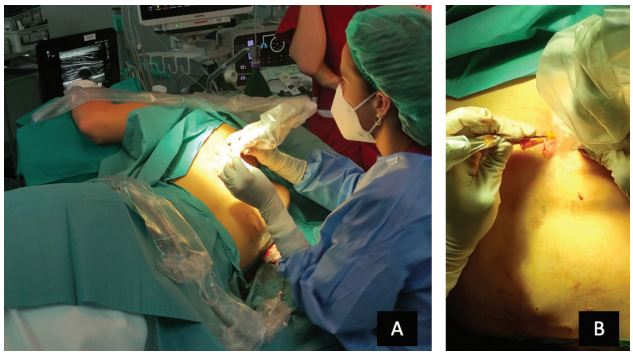

Fig. 2 Percutaneous cryoanalgesia process under sterile conditions and controlled by ultrasound. (**A**) Anesthesiologist performing PCr process with ultrasound monitor and ultrasound probe to control the process at all times. (**B**) Passage of the cryoneedle through the 18-G angiocatheter.

through the contralateral hemithorax. A Blake was placed as a guide for placement of the bar (MedXpert Universal System), previously designed individually for each patient. The bar was introduced with the convexity to the posterior and then flipped so that the convexity was anterior, which elevated the sternum and corrected the PE. The bar was fixed on the left hemithorax with a stabilizer and on the right side with stitches.

Postoperative Care

Postoperative care and analgesic protocol were established by the Pain Unit of our Hospital and were applied in the same way in all patients. After leaving the operating room, the patients were admitted for 24 hours in the Anesthesia Resuscitation Unit, maintaining continuous PCA at 2 mL/h (fentanyl 0.5 µg/kg/mL, with a maximum of 25 µg/mL; and metamizole magnesium 4 mg/kg/mL, with a maximum of 200 mg/mL), which was subsequently progressively decreased at first to 1-mL boluses, then intravenous analgesia, alternating analgesia, and oral analgesia according to the degree of pain evaluated with the visual analog scale (VAS). Pain assessment was performed twice a day, once by the Pain Unit and once by the nursing staff during standardized movement. Pain units measured with the visual analgesic scale were between 0 and 10, where a score of 3 or less meant mild pain, between 4 and 7 meant moderate pain, and 8 or greater meant severe pain. The criteria for discharge home were: pain controlled with oral analgesia (paracetamol, metamizole, or dexketoprofen), safe ambulation, good tolerance to enteral feeding, and adequate diuresis. Outpatient visits were scheduled in the first and third postoperative weeks, 2 months, 4 months, 6 months, and 1 year after surgery. Each visit consisted of an anamnesis on the evolution, pain, possible complications, degree of satisfaction, and analgesic intake. It was accompanied by a physical examination evaluating the incision sites, chest wall mobility, and aesthetic aspect.

Statistical Analysis

Data were collected using Microsoft Excel software version 16.35, and were analyzed with IBM SPSS Statistics 25.0 software. Kolmogorov–Smirnoff and Shapiro–Wilk test were used to compare the distributions of numerical variables. Continuous variables were expressed as mean and standard deviation (SD) when normally distributed and as median and interquartile range (Q1–Q3) when not normally distributed. Categorical variables were expressed as absolute frequencies (n) and percentages (%). Quantitative data were analyzed with Student's t-test in normally distributed variables or the Mann–Whitney U test otherwise, and categorical data were analyzed with the χ^2 or the Fisher exact test when the first one could not be applied. Statistical significance was established with a value of $p < 0.05$.

Results

A total of 20 patients (90% males; 10% females) were included, with a mean age of 15.1 ± 0.9. There were 12 patients in the PCrSD group and 8 patients in the PCr48 group. There were no significant differences in demographic, clinical, and radiological characteristics between the two groups (►Table 1). The main reason for consultation was aesthetic (100%), followed by dyspnea (20%), pain (5%), and dizziness (5%).

Opioid Use, Degree of Pain (VAS), and Length of Hospital Stay

Patients in the PCrSD group had a significant longer use of opioids in the form of continuous PCA (32 vs. 24 hours; $p = 0.031$) and a higher number of rescues than those in the PCr48 group (18 vs. 11 boluses, respectively; $p = 0.042$). Pain assessed with the analog scale (VAS) on the first postoperative day was greater in the PCrSD group, a difference that was statistically significant (5.5 vs. 2 points; $p = 0.043$). ►Table 2 shows the analgesia data and degree of pain assessed with the visual analgesic scale. Length of hospital stay was significantly shorter in PCr48 group when compared with PCrSD patients (3.5 vs. 5 days, respectively; $p < 0.001$).

Cryoanalgesia and Operation Duration

When comparing the median time to perform cryoanalgesia in the PCrSD group with PCr48, no statistically significant differences were observed (63 [56–66] vs. 64 [57–68] min, respectively; $p = 0.910$). In addition, no significant differences were obtained in the time taken to perform surgery between PCrSD and PCr48 (77.5 [62.7–89] vs. 87.5 [76–90] min, respectively; $p = 0.305$).

Complications and Follow-up

No serious complications were recorded intraoperatively, during cryoanalgesia, or during follow-up in either group. One patient (5%) presented with acute urinary retention requiring bladder catheterization in the PCrSD group. Two patients (25%) in the PCr48 group developed a mild hematoma that resolved by itself. Three patients, two in PCr48 (25%) and one (8.3%) in the PCrSD group, presented with mild hyperpigmentation of the wounds, which after 6 months of follow-up has not disappeared. No patient had to be

Downloaded by: HOSPITAL LA PAZ. Copyrighted material.

 © 2021. Thieme. All rights reserved.

Table 1 Demographic, clinical, and radiological features

	PCrSD ($n = 12$)	PCr48 ($n = 8$)	*p*-Value
Age (y), average ± SD	15.2 ± 0.9	14.8 ± 0.8	0.473
Gender, *n* (%)			
Males	10 (83.3)	8 (100)	0.224
Females	2 (16.7)	–	
Body mass index, average ± SD	18.8 ± 1.8	20 ± 2.9	0.473
ASA, *n* (%)			
ASA I	3 (25)	2 (25)	0.463
ASA II	7 (58.3)	6 (75)	
ASA III	2 (16.7)	–	
Spirometry, *n* (%)			
Normal	10 (83.3)	8 (100)	0.224
Slight alteration	2 (16.7)	–	
Echocardiography, *n* (%)			
Normal	11 (91.6)	7 (87.5)	0.761
Slight alteration	1 (8.4)	1 (12.5)	
RM (dimensionless), average ± SD			
Haller index			
Inspiration	5.1 ± 2.4	4.3 ± 1.5	0.384
Expiration	6.7 ± 3.6	6.7 ± 3.6	0.734
Correction index			
Inspiration	40.1 ± 11	34 ± 14	0.157
Expiration	45.9 ± 11	40 ± 19	0.115

Abbreviations: ASA, American Society of Anesthesiologists Physical Status; PCrSD, PCr on the same day; PCr48, PCr 48 hours before surgery; RM, magnetic resonance.

Table 2 Analgesia and degree of pain assessed by visual analog scale (VAS) during postoperative days (DPO)

	PCrSD ($n = 12$)	PCr48 ($n = 8$)	*p*-Value
Analgesia			
Opioid consumption			
Continuous PCA (h), median (Q1–Q3)	32 (32–35)	24 (23–25)	0.031
Bolus PCA (units), median (Q1–Q3)	18 (15–20)	11 (8.7–12.5)	0.042
Nonopioid analgesia consumption			
IV analgesia	24 (10–24)	24 (12–27)	0.624
IV/O analgesia (h), median(Q1–Q3)	12 (7–24)	28 (12–24)	0.238
Oral analgesia (h), median(Q1–Q3)	24 (24–24)	10 (10–23)	0.007
Degree of pain (VAS)			
DPO 1, median (Q1–Q3)	5.5 (3.2–6.7)	2 (1.2–3)	0.043
DPO 2, median (Q1–Q3)	3.5 (1–6)	3.5 (1–6)	0.910
DPO 3, median (Q1–Q3)	4 (1–6)	1 (1–1)	0.115
DPO 4, median (Q1–Q3)	1 (1–1)	1 (1–1)	0.238
DPO 5, median (Q1–Q3)	1 (1–1)	1 (1–1)	0.115

Abbreviations: DPO, postoperative day; IV, intravenous; O, oral; PCA, patient-controlled analgesia.

Downloaded by: HOSPITAL LA PAZ. Copyrighted material.

 © 2021. Thieme. All rights reserved.

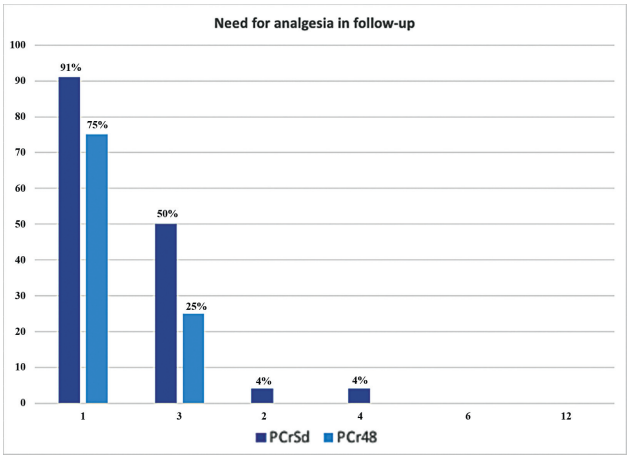

Fig. 3. Consumption of oral analgesics at follow-up. The x-axis shows the week/month of consultation (1st postoperative week, 3rd postoperative week, 2nd, 4th, 6th, and 12th month; respectively). Above the bars is the percentage of patients using oral analgesia in each group.

reoperated due to bar displacement. Follow-up was performed in the first postoperative week, third postoperative week, 2 months, 4 months, 6 months, and 1 year. All patients showed a high degree of satisfaction with their body image 1 year after surgery. Regarding pain assessment, ►**Fig. 3** shows the results of alternate oral analgesia consumption in the months following surgery.

Discussion

This is the first study to compare PCr performed 48 hours before the Nuss procedure with that performed on the same day immediately prior to surgery. Minimally invasive repair represented an advance in the treatment of PE, with smaller incisions, shorter surgical time, no cartilage resection or osteotomies, and less blood loss, compared with the Ravitch technique.[3,5,6] Similarly, the application of thoracoscopic cryoanalgesia has been able to provide long-lasting pain control, decreased hospital stay, and reduced opioid use, as reflected in the series published so far.[2,4,17–23] With the aim of further improving the use of cryotherapy and avoiding possible complications related to thoracoscopy,[21] we applied ultrasound-guided percutaneous cryotherapy prior to the Nuss procedure obtaining encouraging results in terms of hospital stay, pain, and opioid use. Since the effect of cryotherapy begins approximately 6 to 10 hours after application and in some studies even exceeds 24 hours, we wanted to optimize the procedure by performing it 48 hours prior to the shorter hospital stay (LOS) and with less use of opioids and less pain, which were significant findings.

In contrast to its advantages, the application of cryoanalgesia increases surgical times for both thoracoscopic and percutaneous techniques. While in our experience the mean cryoanalgesia time and operating room time was 63 and 63.5 minutes, respectively , other authors such as Graves et al have reported an increased operative time of 69 minutes with thoracoscopic cryotherapy performed just prior to the Nuss procedure.[17] However, the reduction in hospital stay and the lower consumption of opioid medication provide a lower hospital cost, as can be seen in the analysis of Aiken et al.[24] In the future, with experience and improvement of the technique and its routine application, surgical time will be reduced and, consequently, so will costs.

However, complications associated with cryoanalgesia by thoracoscopy, such as pneumothorax, pleural effusion, pneumonia, wound infection, or other skin lesions, are largely due to tissue contact with the cryoprobe. Although in most series a very small percentage of these are reported, Parrado et al reported that 9% of postoperative pneumothoraces in their study required a drainage tube or Sun et al reported a higher percentage of bar displacement in patients treated with PCr.[11,25] Different improvements have been designed to avoid this, such as the Parrado protective sheath, the use of a chest tube covering the cryoprobe described by Morikawa et al, or the use of a new cryoprobe reported by Torre et al.[2,11,26] In our center, we eliminated the thoracoscopic approach and used the percutaneous approach with needle protecting the tissues with an angiocatheter so as not to damage them by contact and avoiding the risk of injury by contact of the cold with the lung, great vessels, or mediastinum by not entering the thoracic cavity. Our series reports no major intraoperative or postoperative complications during the cryoanalgesia process. The only problem with PCr was the appearance of two mild hematomas in two patients that resolved without major complications. No short- or medium-term complications were observed during outpatient follow-up. Neuralgia following thoracoscopic cryoanalgesia has been reported in some studies; however, in our patients, it was not found in the immediate postoperative period or in the short-term follow-up, so we believe that it may be an advantage associated with the technique. Thus, cryoanalgesia is considered a safe procedure with minimal risk of complications when performed with percutaneous approaches under imaging guidance. Studies with long-term follow-up will show more data to be able to make more reliable conclusions regarding this issue.[6,27–29]

In addition to the complications related to the analgesic and surgical technique, we must take into account those related to the use of opiates, where nausea and vomiting were the most frequently reported in both the groups (50% of patients). After the PE procedure, all our patients maintained with PCA for at least 24 hours.

When comparing the two groups, patients who underwent PCr48h required fewer hours of PCA in the immediate postoperative pain than those who underwent PCrSD, which further reinforces the efficacy of PCr48. However, the elimination of PCA in the postoperative period, in addition to eliminating the adverse effects of opioids (itching, acute urinary retention, constipation, nausea, and vomiting), could further shorten the hospital stay, as shown by Sujka et al[30] in their study with 1.5-day stays or Graves et al with 3-day postoperative without the use of PCA.[17] In the future and after observing the initial results, one of our main objectives will be to remove the PCA placed on patients in the immediate postoperative period and eliminate the 24 hours in the Post Anesthesia Resuscitation Unit to improve the postoperative period of the patients.

Downloaded by: HOSPITAL LA PAZ. Copyrighted material.

 © 2021. Thieme. All rights reserved.

The long-term analgesia provided by cryoablation is the main advantage of its use. In our patients, at follow-up for 1 year after surgery, no severe pain is reported. For this reason, it has been used for a wide range of procedures, especially in adults, such as open thoracotomies, postherpetic neuralgia, postoperative inguinal herniorrhaphy, and joint pain.[8,11,31–36] We have also found positive results in its application in the Ravitch technique for correction of PE and other thoracic deformities.[37,38] In its percutaneous modality, the most recent review reports three cases of mastectomy with very good results.[39] This is why we encourage the search for or broadening of the field of use of PCr in other pediatric surgical procedures associated with marked postoperative pain.

We consider PCr 48 hours before the Nuss surgery an effective and safe pain control technique. In addition to being less invasive than thoracoscopic cryoanalgesia, it reduces the length of hospital stay, degree of pain on the first postoperative day, and use of opioids. Finally, we believe that this technique can be used in other pediatric procedures with long postoperative pain.

The major limitation of our study is the small sample size, although the groups were homogeneous and can therefore be considered comparable. As we increase our cohort, we will better define the factors that may contribute to a greater benefit of cryoanalgesia. Another limitation is its retrospective single-center design. Finally, long-term effects and complications could not be clearly delineated because our median follow-up period was 6.5 months. Future reviews will include long-term outcomes, up to the removal of the bar.

Conclusion

The application of PCr performed 48 hours before the Nuss technique is associated with a shorter hospital stay, reduces opioid use, and postoperative pain when compared with PCr applied on the same day of surgery, while offering equivalent surgical times and complications. However, it is a preliminary study to describe our experience and provide input for future research.

Funding

Dr. María Velayos reports support for the present manuscript (e.g., funding, provision of study materials, medical writing, article processing charges, etc.) and receipt of equipment, materials, drugs, medical writing, gifts, or other services from MedXpert Universal System and Metrum Cryoflex.

Conflict of Interest

The authors have no conflicts of interest relevant to this article to disclose.

References

1 de Oliveira Carvalho PE, da Silva MVM, Rodrigues OR, Cataneo AJM. Surgical interventions for treating pectus excavatum. Cochrane Database Syst Rev 2014;2014(10):CD008889

2 Morikawa N, Laferriere N, Koo S, Johnson S, Woo R, Puapong D. Cryoanalgesia in patients undergoing Nuss repair of pectus excavatum: technique modification and early results. J Laparoendosc Adv Surg Tech A 2018;28(09):1148–1151

3 Nuss D, Kelly RE Jr, Croitoru DP, Katz ME. A 10-year review of a minimally invasive technique for the correction of pectus excavatum. J Pediatr Surg 1998;33(04):545–552

4 Kelly RE, Goretsky MJ, Obermeyer R, et al. Twenty-one years of experience with minimally invasive repair of pectus excavatum by the Nuss procedure in 1215 patients. Ann Surg 2010;252(06): 1072–1081

5 Mao YZ, Tang S, Li S. Comparison of the Nuss versus Ravitch procedure for pectus excavatum repair: an updated meta-analysis. J Pediatr Surg 2017;52(10):1545–1552

6 Graves C, Idowu O, Lee S, Padilla B, Kim S. Intraoperative cryoanalgesia for managing pain after the Nuss procedure. J Pediatr Surg 2017;52(06):920–924

7 Kelly RE Jr, Shamberger RC, Mellins RB, et al. Prospective multicenter study of surgical correction of pectus excavatum: design, perioperative complications, pain, and baseline pulmonary function facilitated by internet-based data collection. J Am Coll Surg 2007;205(02):205–216

8 Densmore JC, Peterson DB, Stahovic LL, et al. Initial surgical and pain management outcomes after Nuss procedure. J Pediatr Surg 2010;45(09):1767–1771

9 Ghionzoli M, Brandigi E, Messineo A, Messeri A. Pain and anxiety management in minimally invasive repair of pectus excavatum. Korean J Pain 2012;25(04):267–271

10 Papic JC, Finnell SME, Howenstein AM, Breckler F, Leys CM. Postoperative opioid analgesic use after Nuss versus Ravitch pectus excavatum repair. J Pediatr Surg 2014;49(06):919–923, discussion 923

11 Parrado R, Lee J, McMahon LE, et al. The use of cryoanalgesia in minimally invasive repair of pectus excavatum: lessons learned. J Laparoendosc Adv Surg Tech A 2019;29(10):1244–1251

12 Dekonenko C, Dorman RM, Duran Y, et al. Postoperative pain control modalities for pectus excavatum repair: a prospective observational study of cryoablation compared to results of a randomized trial of epidural vs patient-controlled analgesia. J Pediatr Surg 2020;55(08):1444–1447

13 Protopapas AD, Athanasiou T. Peri-operative data on the Nuss procedure in children with pectus excavatum: independent survey of the first 20 years' data. J Cardiothorac Surg 2008;3(01):40

14 Reinoso-Barbero F, Fernández A, Durán P, Castro LE, Campo G, Melo MM. Thoracic epidural analgesia vs patient-controlled analgesia with intravenous fentanyl in children treated for pectus excavatum with the Nuss procedure [in Spanish]. Rev Esp Anestesiol Reanim 2010;57(04):214–219

15 Parrado RH, Thornburg D, Kang P, McMahon LE. Elastomeric pain pumps as an adjunct for postoperative pain control after minimally invasive repair of pectus excavatum. J Laparoendosc Adv Surg Tech A 2021;31(03):331–335

16 Ahiskalioglu A, Kucun T, Yayik AM, Ulas AB, Ates İ Ultrasound-guided transversus thoracis muscle plane block provides effective postoperative analgesia for pediatric open pectus carinatum surgery: first report. Pain Med 2021;22(05):1233–1235

17 Graves CE, Moyer J, Zobel MJ, et al. Intraoperative intercostal nerve cryoablation during the Nuss procedure reduces length of stay and opioid requirement: a randomized clinical trial. J Pediatr Surg 2019;54(11):2250–2256

18 Keller BA, Kabagambe SK, Becker JC, et al. Intercostal nerve cryoablation versus thoracic epidural catheters for postoperative analgesia following pectus excavatum repair: preliminary outcomes in twenty-six cryoablation patients. J Pediatr Surg 2016;51 (12):2033–2038

19 Keppler-Noreuil KM, Rios JJ, Parker VER, et al. PIK3CA-Related Overgrowth Spectrum (PROS): diagnostic and testing eligibility

Downloaded by: HOSPITAL LA PAZ. Copyrighted material.

 © 2021. Thieme. All rights reserved.

criteria, differential diagnosis, and evaluation. Am J Med Genet A 2015;167A(02):287–295
20 Arshad SA, Hatton GE, Ferguson DM, Li LT, Austin MT, Tsao KPAPS SPONSOR. Cryoanalgesia enhances recovery from minimally invasive repair of pectus excavatum resulting in reduced length of stay: a case-matched analysis of NSQIP-Pediatric patients. J Pediatr Surg 2021;56(07):1099–1102
21 Gallardo CC, Martínez J, Bellía-Munzon G, et al. Thoracoscopic cryoanalgesia: a new strategy for postoperative pain control in minimally invasive pectus excavatum repair. Cir Pediatr 2020;33 (01):11–15
22 Kim S, Idowu O, Palmer B, Lee SH. Use of transthoracic cryoanalgesia during the Nuss procedure. J Thorac Cardiovasc Surg 2016;151(03):887–888
23 Cha PI, Min JG, Patil A, Choi J, Kothary NN, Forrester JD. Efficacy of intercostal cryoneurolysis as an analgesic adjunct for chest wall pain after surgery or trauma: systematic review. Trauma Surg Acute Care Open 2021;6(01):e000690
24 Aiken TJ, Stahl CC, Lemaster D, et al. Intercostal nerve cryoablation is associated with lower hospital cost during minimally invasive Nuss procedure for pectus excavatum. J Pediatr Surg 2021;56(10): 1841–1845
25 Sun RC, Mehl SC, Anbarasu CR, et al. Intercostal cryoablation during Nuss procedure: A large volume single surgeon's experience and outcomes. J Pediatr Surg 2021;56(12):2229–2234
26 Torre M, Mameli L, Bonfiglio R, et al. A new device for thoracoscopic cryoanalgesia in pectus excavatum repair: preliminary single center experience. Front Pediatr 2021;8:614097
27 Ju H, Feng Y, Yang BX, Wang J. Comparison of epidural analgesia and intercostal nerve cryoanalgesia for post-thoracotomy pain control. Eur J Pain 2008;12(03):378–384
28 Roxburgh JC, Markland CG, Ross BA, Kerr WF. Role of cryoanalgesia in the control of pain after thoracotomy. Thorax 1987;42(04): 292–295
29 Yang MK, Cho CH, Kim YC. The effects of cryoanalgesia combined with thoracic epidural analgesia in patients undergoing thoracotomy. Anaesthesia 2004;59(11):1073–1077
30 Sujka J, Benedict LA, Fraser JD, Aguayo P, Millspaugh DL, St. Peter SD. Outcomes using cryoablation for postoperative pain control in children following minimally invasive pectus excavatum repair. J Laparoendosc Adv Surg Tech A 2018;28(11):1383–1386
31 Keller BA, Kabagambe SK, Becker JC, et al. Intercostal nerve cryoablation versus thoracic epidural catheters for postoperative analgesia following pectus excavatum repair: preliminary outcomes in twenty-six cryoablation patients. J Pediatr Surg 2016;51 (12):2033–2038. Doi: 10.1016/j.jpedsurg.2016.09.034
32 Trescot AM. Cryoanalgesia in interventional pain management. Pain Physician 2003;6(03):345–360
33 Filippiadis D, Efthymiou E, Tsochatzis A, Kelekis A, Prologo JD. Percutaneous cryoanalgesia for pain palliation: current status and future trends. Diagn Interv Imaging 2021;102(05):273–278
34 Evans PJD, Lloyd JW, Jack TM. Cryoanalgesia for intractable perineal pain. J R Soc Med 1981;74(11):804–809
35 Gabriel RA, Ilfeld BM. Novel methodologies in regional anesthesia for knee arthroplasty. Anesthesiol Clin 2018;36(03):387–401
36 Green CR, de Rosayro AM, Tait AR. The role of cryoanalgesia for chronic thoracic pain: results of a long-term follow up. J Natl Med Assoc 2002;94(08):716–720
37 Gologorsky R, Ewbank C, Idowu O, Kim S. Use of cryoanalgesia as a postoperative pain management for open pectus carinatum repair. Pediatr Surg Int 2021;37(01):179–181
38 Pilkington M, Harbaugh CM, Hirschl RB, Geiger JD, Gadepalli SK. Use of cryoanalgesia for pain management for the modified ravitch procedure in children. J Pediatr Surg 2020;55(07):1381–1384
39 Gabriel RA, Finneran JJ, Swisher MW, et al. Ultrasound-guided percutaneous intercostal cryoanalgesia for multiple weeks of analgesia following mastectomy: a case series. Korean J Anesthesiol 2020;73(02):163–168

Downloaded by: HOSPITAL LA PAZ. Copyrighted material.

 © 2021. Thieme. All rights reserved.